

Original article

Comparison of digital subtraction angiography with gadolinium-enhanced magnetic resonance angiography in the diagnosis of renal artery stenosis

J. Thornton¹, J. O'Callaghan¹, J. Walshe², E. O'Brien², J. C. Varghese¹, M. J. Lee¹

Department of ¹ Radiology and ² Medicine, Beaumont Hospital, Dublin 9, Ireland; and Royal College of Surgeons in Ireland, Dublin 2, Ireland

Received: 17 March 1998; Revision received: 30 June 1998; Accepted: 28 August 1998

Abstract. Renal artery stenosis (RAS) is a treatable cause of hypertension and renal failure for which no ideal screening technique is currently available. We evaluated the use of dynamic gadolinium-enhanced magnetic resonance angiography (MRA) for the diagnosis of RAS. Sixty-two patients with secondary hypertension were enrolled in the study. All patients had conventional renal angiography and gadolinium enhanced MRA. The sequence used was a 3D FMP SPGR sequence with the following parameters (TR: 26 ms, TE: 6.9 ms, flip angle 40°, field of view 36 × 36 cm, matrix 246 × 256, 1 excitation). Gadolinium 0.3 mmol/kg was administered and 60 1.5-mm-thick partitions were obtained over a duration of 3.5 min. The MRA images were then compared with conventional digital subtraction angiography (DSA) images. Conventional DSA demonstrated 138 renal arteries, whereas gadolinium-enhanced MRA demonstrated 129 (93 %). Twenty-one renal artery stenoses and four occluded arteries were seen at conventional DSA. Gadolinium-enhanced MRA had a sensitivity of 88 %, specificity of 98 %, accuracy of 96 %, positive predictive value of 92 % and negative predictive value of 97 % when compared with conventional DSA. Gadolinium-enhanced MRA is an accurate technique for identifying patients with RAS. It is less sensitive in picking up accessory renal arteries.

Key words: Renal artery stenosis – Magnetic resonance angiography

Introduction

Renal artery stenosis (RAS) is well recognised as a significant cause of hypertension and renal failure. The incidence of RAS in the general hypertensive population

is between 3 and 10 % [1]. Certain sub-groups of patients are reported to have a higher prevalence. For example, in one study 25–45 % of hypertensive patients with peripheral vascular disease were found to have significant (> 50 %) RAS at angiography [2]. In addition, RAS is estimated to be the cause of hypertension in up to 33 % of patients over the age of 60 years [3]. Derkx et al. showed that 40 % of patients referred to hypertensive clinics were found to have RAS [4]. Renal artery stenosis may also play a part in the development of chronic renal failure. In one study, 14 % of patients over 50 years old with chronic renal failure requiring renal replacement therapy in the United Kingdom were found to have angiographic evidence of RAS [5]. Furthermore, the presence of RAS is known to progress to eventual occlusion in approximately 44 % of patients [6, 7].

Several studies have demonstrated that revascularisation of kidneys in patients with RAS leads to an improvement in blood pressure control as well as renal function. Renal revascularisation may involve percutaneous renal artery angioplasty, percutaneous renal artery stenting or surgical revascularisation [8–11]. However, despite the significant incidence of RAS within the hypertensive population and the ability to treat this disease with good results, there is still a reluctance to submit all patients with hypertension to conventional angiography. Angiography is an invasive procedure involving arterial catheterisation, administration of contrast material and appropriate patient after-care to avoid complications. Ideally all patients with hypertension should be screened for RAS. However, conventional angiography is too invasive a procedure to perform on all hypertensive patients. The holy grail of renal vascular imaging is the development of a non-invasive imaging test with sufficient accuracy to introduce as a screening technique. To date, most non-invasive imaging tests, such as ultrasound and nuclear medicine studies, are not accurate enough or have not gained enough credibility to be introduced as screening techniques.

The technique of magnetic resonance angiography (MRA) takes many forms and has been used with vary-

ing success when imaging the renal arteries. However, compared with ultrasound and nuclear medicine, the renal arteries are directly visualised making MRA an attractive proposition for screening. In an attempt to evaluate the accuracy of MRA we performed a study to evaluate three-dimensional time-of-flight (TOF) MRA after triple-dose gadolinium administration in patients suspected of having RAS and compared this MRA technique with conventional angiography.

Materials and methods

Sixty-two consecutive patients with clinically suspected secondary hypertension referred for conventional renal angiography were enrolled in the study. Informed consent was obtained from all patients and the study protocol was approved by the hospital ethics committee. Each patient had conventional renal angiography and gadolinium-enhanced 3D MRA imaging for evaluation of the renal arteries.

Conventional angiography was performed through a femoral artery puncture using the Seldinger technique. A 5-F pigtail catheter was placed (William Cook, Europe, Verskof BF, Denmark) in the aorta at the level of the renal arteries. A flush aortic injection of 45 ml of iohexol (Omnipaque 300, Nycomed, Oslo, Norway) at 15 ml/s was performed and images were taken in the anteroposterior plane. If the renal arteries were not clearly depicted, additional oblique projections were obtained to identify the origins of the renal arteries. All images were obtained using digital subtraction angiography (DSA).

Magnetic resonance angiography of the renal arteries was performed using a 1.5-T GE unit (General Electric, Milwaukee, Wis.). Following a sagittal localiser, a 3D TOF sequence was performed in the axial plane to cover the location of renal arteries. A 3D FMP SPGR sequence was used with the following imaging parameters: TR: 26 ms, TE: 6.9 ms, flip angle 40°, field of view (FOV) 36 × 36 cm, matrix 256 × 256, 1 excitation (NEX). A total of 60 × 1.5-mm-thick partitions were acquired in 3 min, 32 s. Triple dose gadolinium (0.3 mmol/kg) was administered during image acquisition. This was administered through an IV cannula which was placed prior to the patient entering the MR scanner. A long-connecting tubing permitted gadolinium administration without moving the patients out of the gantry. Contrast administration by hand injection was commenced 10–20 s prior to the start of the imaging sequence and was continued at a rate such that the infusion of contrast was maintained throughout the TOF sequence until approximately 30 s before the end of imaging. The images were reconstructed using a combination of vascular and reformatting software packages.

Both the gadolinium-enhanced FMP-SPGR images and the conventional angiographic images were reviewed by three blinded observers experienced in vascular imaging. A consensus opinion was reached in each case. The TOF MRA images were first reviewed followed by conventional angiographic images at a time in-

terval of 1 month. Images were analysed for the number of renal arteries present, the length of the renal arteries visualised and the presence or absence of stenosis or vessel occlusion. The main renal artery as far as the hilum is considered to be the proximal 60% with the intra-renal portion making up the remaining 40%; thus, if the renal artery was visualised half way to the hilum, it was considered as the proximal 30%. Only stenoses greater than 50% on conventional angiography were considered for the purposes of this study. The stenoses were graded by visual inspection.

The results were analysed and the 3D MRA study was compared with the gold standard of conventional DSA.

Results

In all 62 patients the two imaging studies were available for comparison (Fig. 1). Conventional renal angiography demonstrated 138 renal arteries. This included 4 patients with renal transplants, 1 patient who had a previous nephrectomy and 14 patients with a total of 19 accessory renal arteries. Of the 138 renal arteries, there were 21 stenotic arteries (Figs. 2, 3), 4 occluded arteries (Fig. 4) and 1 major branch occlusion (Table 1).

Gadolinium-enhanced 3D TOF imaging was considered of diagnostic quality in all patients. A total of 129 of 138 (93%) renal arteries were visualised. The 9 arteries not seen were all accessory renal arteries (Fig. 4). Twenty-one renal artery stenoses were demonstrated with 19 of these correlating with conventional angiography. In addition, gadolinium-enhanced 3D MRA diagnosed all 4 renal artery occlusions but failed to diagnose the branch occlusion; thus, there were two false-positive (Fig. 4) and three false-negative results encountered with gadolinium-enhanced 3D TOF MRA. With gadolinium-enhanced MRA the parenchymal vessels were never seen. The average length of renal artery seen with gadolinium-enhanced 3D MRA was 40%. Of the 21 stenotic renal arteries, 1 was due to fibro-muscular hyperplasia (Fig. 5). This diagnosis was confirmed on MRA. Another patient with a single kidney was found to have a renal artery aneurysm seen at both DSA and MRA.

The sensitivity and specificity of gadolinium-enhanced 3D MRA in detecting RAS and occlusion was 88 and 98%, respectively. The accuracy was 96%. The positive predictive value was 92% and the negative predictive value was 97%.

Discussion

Magnetic resonance angiography is evolving as a useful non-invasive technique for evaluating many arterial systems within the body [12–15]. In the evaluation of RAS, TOF techniques and phase-contrast techniques were first used. Sensitivities and specificities for the detection of RAS in these early studies were encouraging despite the often small patient numbers.

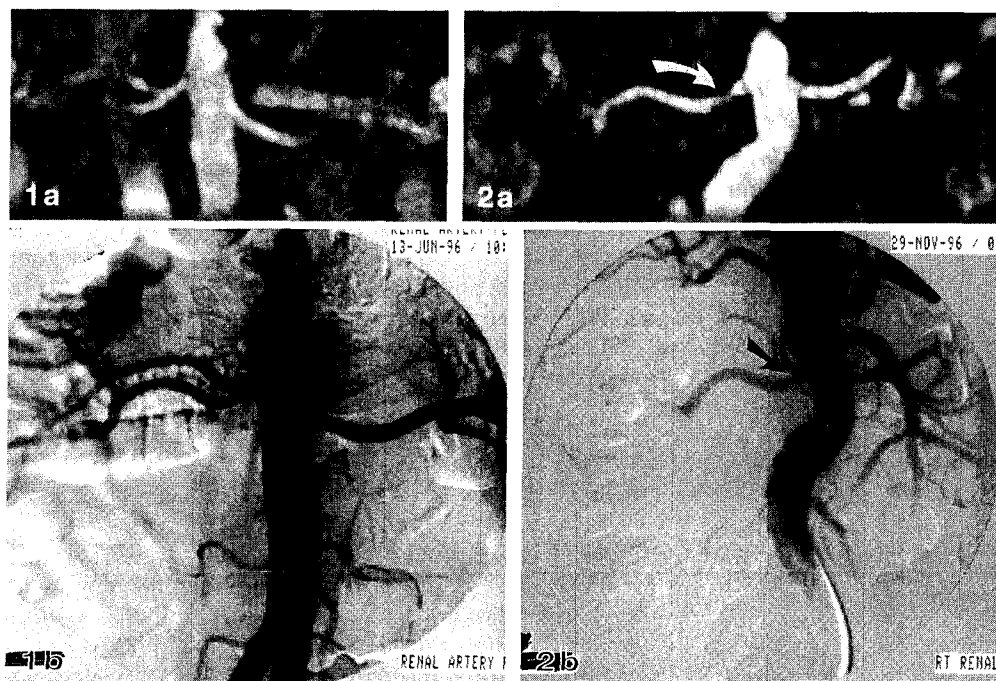


Fig. 1. **a** Reformatted gadolinium-enhanced magnetic resonance angiography (MRA) image demonstrates no renal artery stenosis (RAS) but early bifurcation of the renal artery on the right. **b** Digital subtraction angiography confirms the absence of any RAS and correlates well with MRA

Fig. 2. **a** Reformatted gadolinium-enhanced MRA image demonstrates a stenosis (arrow) in the proximal portion of the right renal artery. Mild post-stenotic dilatation is also noted. **b** Digital subtraction angiography on the same patient confirms the presence of a stenosis (arrow) in the right renal artery proximally

Debatin et al. reported that a combination of 2D coronal TOF and axial- and coronal-phase contrast imaging of renal arteries demonstrated a sensitivity of 87% and specificity of 97% in detecting 15 renal artery stenoses [16]. Gedroyc et al. [17] evaluated 3D phase contrast in 74 patients. It was non-diagnostic in 14 patients. The calculated sensitivity and specificity were 84 and 91%, respectively in 37 renal artery stenoses. De Haan et al. [18] demonstrated no benefit with the additional use of systolic and diastolic gating in the detection of significant renal stenoses using 3D phased-contrast MRA. These, in combination with other studies from DeCobelli et al. [19] and Loubeyre et al. [20], shows that although phase contrast can produce impressive images, there are numerous problems including long acquisition time, limited acquisition volume with reduced detection rate of accessory vessels and an unacceptable rate of non-diagnostic studies. Using a non-contrast 2D TOF sequence in 21 patients, Servois et al. demonstrated a sensitivity of 70–85% and a specificity of 78–86% for detecting RAS > 50% [21]. Also using a 2D TOF MRA sequence Ecklund et al. demonstrated seven of eight significant renal artery stenoses (> 50%) in 20 patients [22]. Similarly, in a study with 24 significant (> 50%) renal artery stenoses discovered at angiography, 3D TOF without contrast had a sensitivity of 100%, specificity of 76% and positive predictive value of 54% [23]. Using a dynamic 3D SPGR sequence similar to ours, Rieumont et al. obtained a sensitivity of 100%, specificity of 71%, negative predictive value of 100% and a positive predictive value of 89% in 30 patients with significant stenosis-occlusive disease in 42 vessels [24].

One of the problems that became apparent when using the TOF technique was the loss of signal intensity from “in-plane” flow. To overcome this, Prince pro-

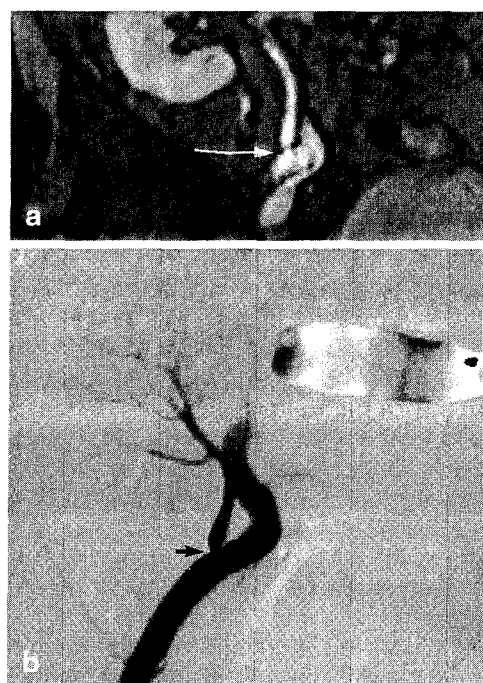


Fig. 3. **a** Reformatted gadolinium-enhanced MRA image of a transplant renal artery in the right iliac fossa depicts a short focal stenosis (arrow) at the origin of the transplant renal artery. **b** Digital subtraction angiography in the same patient gives excellent correlation of the anatomy of the transplant artery and also the short focal stenosis (arrow) at its origin

posed using high-dose gadolinium enhancement to boost the signal from blood within the imaging volume [25]. He demonstrated improved signal from the aorta and branch vessels using high-dose gadolinium with a 3D TOF sequence. In the same study he showed an

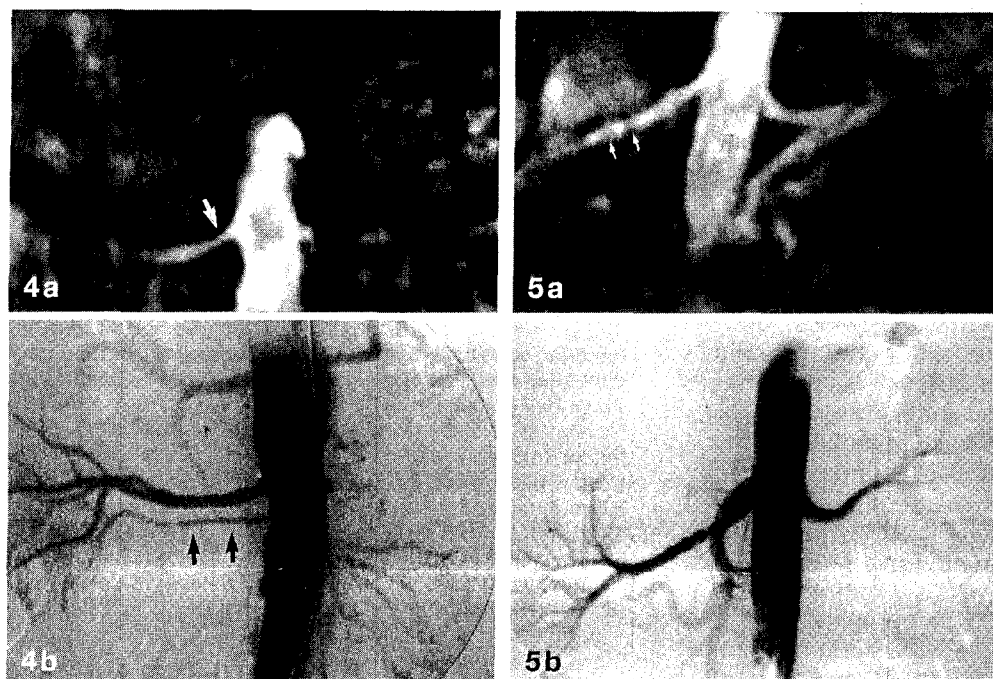


Fig. 4. **a** Reformatted gadolinium-enhanced MRA shows an occlusion of the left renal artery and one right renal artery with an apparent stenosis (arrow). **b** Digital subtraction angiography confirms a left renal artery occlusion and shows an accessory right renal artery. No RAS is evident, indicating that MRA was falsely positive

Fig. 5. **a** Reformatted gadolinium-enhanced MRA image of the renal arteries shows beading (arrows) of the right renal artery in its mid-portion. The appearances were believed to represent fibromuscular hyperplasia. **b** Digital subtraction angiography in the same patient confirms the presence of fibromuscular hyperplasia with beading and stenosis of the right renal artery. Left renal artery appears normal

Table 1. Comparison of digital subtraction angiography (DSA) with gadolinium-enhanced magnetic resonance angiography (MRA). TOF time of flight

	No. of patients	No. of arteries	No. of accessory arteries	Percentage of main artery seen	Stenosis	Occlusion (main artery or branch)
DSA	62	138	19	100	21	5
3D TOF (triple-dose gadolinium)	62	129	10	40	19	4

Table 2. Sensitivity, specificity and accuracy of contrast-enhanced 3D TOF MRA for renal artery stenosis

	Sensitivity (%)	Specificity (%)	Accuracy (%)
3D TOF	88	98	96

85 % sensitivity and 93 % specificity in 59 patients with 20 significant renal artery stenoses. This study also confirmed the safety of high-dose gadolinium which had been described in previous studies [26].

In a later study comparing a combination of five MRA techniques (sagittal T1, coronal 3D SPGR gadolinium enhanced, sagittal 2D TOF, axial 2D TOF and axial 3D phased contrast) with angiography or operative correlation in 153 abdominal vascular segments (iliac, splanchnic or renal), Prince et al. showed a sensitivity of 94 % and a specificity of 98 % for stenoses graded as moderate or severe [27]. In an attempt to corroborate Prince's findings, we used a non-breath-hold 3D gadolinium-enhanced MRA technique.

Our results compare favourably with previously described results with a sensitivity of 88 % and a specificity of 98 % for the detection of RAS. The total number of renal arteries present in this study was 138 with a total of 19 accessory renal arteries. The accuracy of MRA in detecting accessory renal arteries was 53 %. The identi-

fication of accessory renal arteries is important as significant stenosis can be encountered involving accessory renal arteries. Our low accuracy in identifying accessory renal arteries may reflect the axial acquisition of images. Accessory renal arteries may have been outside the imaging volume; however, even when inside the imaging volume, accessory arteries may be missed due to their small size.

Gadolinium-enhanced MRA demonstrated the proximal 40 % of the renal artery in 95 % of patients; in other words, the intra-parenchymal vessels were generally not seen using this technique. This was undoubtedly related to the non-breath-hold technique used with the smaller intra-parenchymal vessels becoming blurred due to breathing and movement artefact. However, this did not result in any diagnostic handicap regarding the identification of renal artery stenoses apart from one branch occlusion. The vast majority of renal artery stenoses occur within the first 1–2 cm of the origin of the renal artery as was the case in this study.

We chose to evaluate the MRA images for the presence or absence of RAS without trying to quantify the stenosis. There are numerous reasons for our course of action. Firstly, the accuracy of any attempted measurement techniques for quantifying RAS on MRA images is dubious. It is well recognised that techniques depending on flow suffer from loss of signal in the presence of

turbulent flow; therefore, stenoses may be exaggerated. Although, with the use of gadolinium, this effect would be minimal, the technique used was a non-breath-hold technique so that measurements of the renal artery would be affected by breathing artefact. Secondly, our algorithm in using MRA as a screening technique would be that any perceived abnormality on MRA would warrant conventional angiography for further evaluation. Conventional angiography is the gold standard and would be required for treatment planning, whether the treatment is by angiographic or surgical methods.

We recognise some limitations in our study. We did not use a breath-hold technique because many of our patients were older and our initial study protocol designated a non-breath-hold technique. Undoubtedly, the faster gradients available on newer MR units, coupled with breath-hold technique and dynamic administration of gadolinium, is thought by some authors to be the most accurate way of examining the renal arteries [28, 29]. Nevertheless, our sensitivity of 95 % and specificity of 99 % in the detection of RAS is encouraging.

In conclusion, non-breath-hold 3D gadolinium-enhanced MRA has a sensitivity of 95 %, a specificity of 99 % and an overall accuracy of 96 % in the detection of RAS in this study. Although larger numbers of patients will have to be enrolled to validate these results, the initial high sensitivity and specificity are encouraging.

References

- Anderson GH, Blakeman N, Streeten DHP (1994) The affect of age on prevalence of secondary forms of hypertension in 4,429 consecutively referred patients. *J. Hypertension* 12: 609–615
- Mourad JJ, Melki JP, Luizy F et al. (1993) Prevalence of anatomic renal artery stenosis in hypertensive patients with peripheral arteritis. *J. Mal Vasc* 18: 299–302
- Dean RH (1985) Renal vascular hypertension. *Curr Probl Surg* 22: 6
- Derkx FHM, Schalekamp MADH (1994) Renal artery stenosis and hypertension. *Lancet* 344: 237–239
- Scoble J, Maher ER, Hamilton G et al. (1989) Atherosclerotic renal vascular disease causing renal impairment: a case for treatment. *Clin Nephrol* 31: 119–122
- Schreiver MJ, Pohl MA, Novick AC (1984) The natural history of atherosclerotic and fibrous disease. *Urol Clin North Am* 11: 383
- Dean RH, Kieffer RW, Smith BM et al. (1981) Renal vascular hypertension, anatomic and renal function changes during drug therapy. *Arch Surg* 116: 1408–1415
- Ramsay LE, Waller PC (1990) Blood pressure responds to percutaneous transluminal angioplasty for reno-vascular hypertension: an overview of published series. *Br Med J* 300: 569–572
- Hanson SJ, Starr SM, Sands E (1992) Contemporary surgical management of renal vascular disease. *J Vasc Surg* 16: 319–331
- Fargany A, Kolettis P, Novic AC (1995) The contemporary role of extra-anatomical surgical renal revascularisation in patients with atherosclerotic renal artery disease. *J Urol* 153: 1798–1802
- Weibull H, Bergqvist D, Bergentz SE et al. (1993) Percutaneous transluminal renal angioplasty versus surgical reconstruction of atherosclerotic renal artery stenosis: a prospective randomized study. *J Vasc Surg* 18: 841–852
- Steiner P, McKinnor GC, Romanowski B, Goedhe SC, Hany T, Debatin JF (1997) Contrast-enhanced, ultrafast 3D pulmonary MR angiography in a single breath-hold: initial assessment of imaging performance. *J Magn Reson Imaging* 7: 177–182
- McCauley TR, Monib A, Dickey KW, Clemett J, Meier GH, Eglin TK, Gusberg RJ, Rosenblatt M, Pollak JS (1994) Peripheral vascular occlusive disease: accuracy and reliability of time-of-flight MR angiography. *Radiology* 192: 351–357
- Quinn SF, Sheley RC, Szumowski J, Shimakawa A (1997) Evaluation of the iliac arteries: comparison of two-dimensional time of flight magnetic resonance angiography with cardiac compensated fast gradient recalled echo and contrast-enhanced three-dimensional time of flight magnetic resonance angiography. *J Magn Reson Imaging* 7 (1): 197–203
- Meaney JF, Prince MR, Nostrant TT, Stanley JC (1997) Gadolinium-enhanced MR angiography of visceral Arteries in Patients with Suspected Chronic Mesenteric Ischaemia. *J Magn Reson Imaging* 7: 171–176
- Debatin J, Spritzer C, Grist T et al. (1991) Imaging of the renal arteries: value of MR angiography. *AJR* 157: 981–990
- Gedroyc P, Neerhut R, Negus R et al. (1995) Magnetic resonance angiography of renal artery stenosis. *Clin Radiol* 50: 436–439
- Haan M de, Kouwenhoven M, Thelissen G et al. (1996) Renovascular disease in patients with hypertension: detection with systolic and diastolic gating in three-dimensional, phase contrast MR angiography. *Radiology* 198: 449–456
- DeCobelli F, Vanzulli A, Sirono S et al. (1997) Renal artery stenosis: evaluation with breath-hold, three-dimensional, dynamic, gadolinium-enhanced versus three-dimensional, phase-contrast MR angiography. *Radiology* 205: 689–695
- Loubeyre P, Troillet P, Cahen R, et al. (1996) MR angiography of renal artery stenosis: value of the combination of three-dimensional time-of-flight and three dimensional phase-contrast MR angiography sequences. *AJR* 167: 489–494
- Servois V, Laissy JP, Ferger C. et al. (1994) Two-dimensional time of flight magnetic resonance angiography of renal arteries without maximum intensity projection: a prospective comparison with angiography in 21 patients screened for renovascular hypertension. *Cardiovasc Intervent Radiol* 17: 138–142
- Ecklund K, Hartnell GG, Hughes LA et al. (1994) MR angiography as the sole method in evaluating abdominal aortic aneurysms: correlation with the conventional techniques and surgery. *Radiology* 192: 345–350
- Loubeyre P, Revel D, Garcia P et al. (1994) Screening patients for renal artery stenosis. The value of three dimensional time of flight MR angiography. *AJR* 162: 847–852
- Rieumont MJ, Kaufman JA, Geller SC et al. (1997) Evaluation of renal artery stenosis with dynamic gadolinium-enhanced MR angiography. *AJR* 169: 39–44
- Prince Martin R (1994) Gadolinium enhanced MR artography. *Radiology* 191: 155–164
- Haustein J, Laniado M, Niendorf NP et al. (1993) Triple dose versus standard dose gadopentetate dimeglumine: a randomised study of 199 patients. *Radiology* 186: 855–860
- Prince MR, Narasimham DL, Stanley JC et al. (1995) Gadolinium enhanced MRA angiography of abdominal aortic aneurysms. *J Vasc Surg* 14: 656–669
- Holland GA, Dougherty L, Carpenter JP et al. (1996) Breath-hold ultrafast three-dimensional gadolinium-enhanced MR angiography of the aorta and the renal and other visceral arteries. *AJR* 166: 971–981
- Snidow JJ, Johnson MS, Harris VJ et al. (1996) Three-dimensional gadolinium-enhanced MR angiography for aortoiliac inflow assessment plus renal artery screening in a single breath hold. *Radiology* 198: 725–732